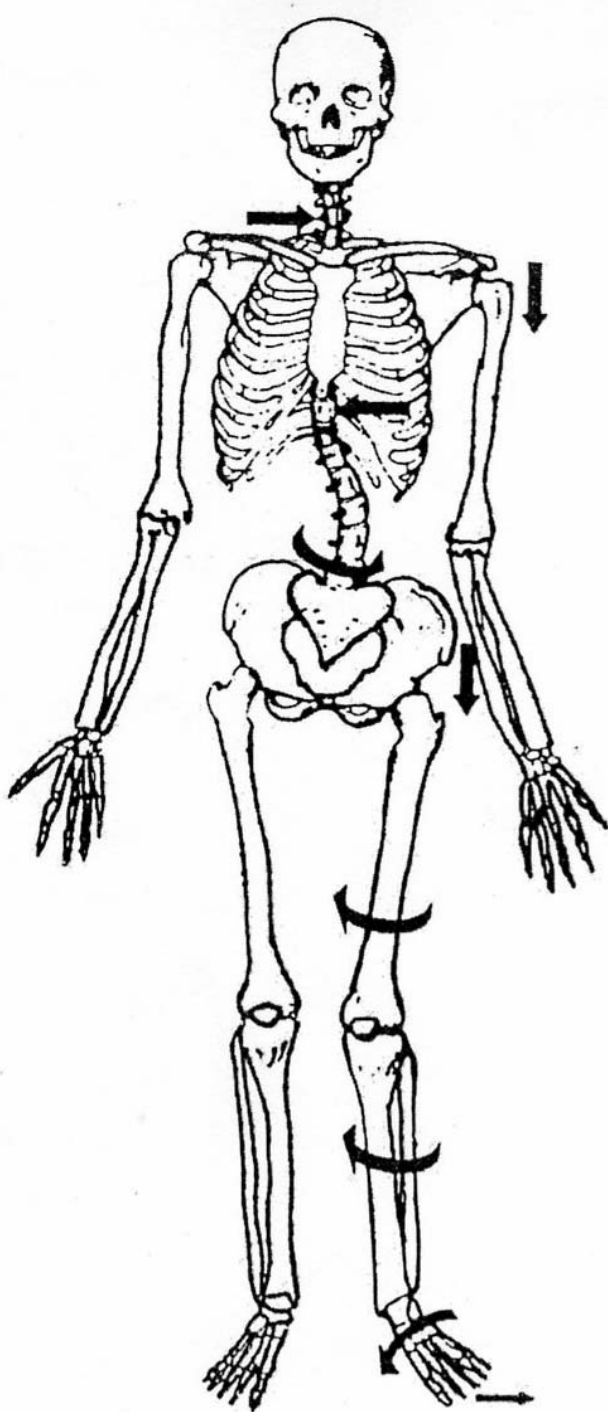


## THE PATTERN UNDER THEIR PAIN

*Ralph Stephens, LMT, NCTMB*

Do you know that there is a common pattern of postural distortion that is the underlying cause for the majority of the pain complaints people report? It is a predisposing factor for many injuries on the job and in athletics. It is prevalent in all age groups above infancy. It manifests as many different pain complaints from head to toe, but it is the same general pattern. If you learn to recognize and correct this pattern, you can have dramatic therapeutic impact quickly, reducing both the symptom and the cause. Do you have a guess what this pattern is?

It is the natural tendency to focus on the symptoms of a condition. After all that is the patient's complaint. If they report pain in the lumbar area, work the low back, maybe if you are creative and adventurous, the entire abdominal wall, as the abdomen is the front of the back so to speak. However, the low back complaint is likely to return periodically or worse, never resolve even temporarily, if the cause is somewhere else in the body, like the pelvis for instance.



*Illustration of the full body distortion caused by an over-pronated left foot*

The body is not a group of separate parts or areas. Everything is interconnected and interrelated. Everything affects everything else, especially when a misalignment in the structure occurs. The feet can affect the jaw. The jaw can affect the pelvis. The human body is an integrated, continuous system. It has only one muscle, "The Muscle." That should make the study of anatomy much easier, but it doesn't, as we need the names of the areas of "The Muscle" for the sake of geography. If you ever get the privilege of observing or performing dissection on a cadaver you will see that the muscles are not nearly as defined as in an anatomy book. "The Muscle" is continuous and must be cut, ripped, and torn apart to isolate a named part of it, such as the gracilis.

To increase your therapeutic impact and to get longer lasting results, don't just put the patient on the table and go to work on the area of their complaint. Take a few minutes extra during your patient intake and check for a causative pattern I call, "The Pronation Syndrome." This common pattern is exhibited in the majority of people to some extent or another. I will explain the general pattern by describing the most common version you will see. However, nothing is always with humanity, so be aware that there are many deviations from this most common form of the syndrome. Follow along on the illustration as I describe the pattern shown.

The pattern is best identified with the patient standing barefoot. The big clue is one arch is lower or flatter than the other. The lower arch side is over-pronating. Sometimes, both sides may be over-pronating, but one is more than the other, or one side is "normal" and the other side lower. It is easy to accomplish this assessment. Just put one finger under the patient's arch. Notice how much of your finger goes under their arch. Then check the other side. Are they the same or different? If one is noticeably lower (flatter) than the other side you are onto a "Pronation Syndrome" case. To confirm this, go around to their backside and observe their Achilles tendon. It will typically be bowed or bowed more on the side with the lower arch instead of its normal straight vertical course. Often these people will have a hypertrophied, tighter, and ischemic medial gastrocnemius head as it is trying valiantly to hold up the collapsing ankle, unsuccessfully. Flat feet can lead to a boatload of problems but that is beyond the scope of this article.

It should be noted that the origination of this syndrome can be the foot, but it may also be the ilium of that side. When the foot over-pronates, the ilium will normally rotate anteriorly. However, if the ilium rotates anteriorly, it can drive the arch inferior into over-pronation. This becomes a chicken and the egg argument that is irrelevant. Whatever presents is what is now. Find it and fix it on both ends as necessary.

Next, look at their knees. Typically, with the feet under the hips and pointed straight ahead, big toes in a straight line, the over-pronating side will be rotated internally. This is because when the forefoot over-pronates, it causes the ankle to invert, tipping the superior calcaneus medially which tips and internally rotates the talus bone. As the talus rotates so does the tibia and the internal rotation is seen at the knee as a patella pointing medially. Often these people present a hypertrophied vastus lateralis that is trying to stop the collapse at its level, again unsuccessfully. However, by trying, it can pull the patella against the femur condyle and contribute to a condromalacia condition. In several studies, over 65% of athletes sustaining ACL injuries over-pronated on the injured side.

The internal rotation continues to the femur, changing its position in the hip joint. This alters the angle of the gluteus muscles pulling the ilium into anterior rotation relative to the other side. Now it gets really interesting.

When one ilium, let's say the left one, goes into anterior rotation (ASIS moving inferior) it twists the sacrum into a compound angle of distortion. The sacrum will move anterior and inferior on the anteriorly rotated left side. This is because the sacrum is on the anterior of the ilium, so as the ilium rotates anteriorly, the sacrum is forced to move with it. L-5 is tightly bound to the sacrum with ligaments, so where goes the promontory of the sacrum, so goes L-5, rotating and tipping. Now the righting reflexes, our sense of balance, really kicks in. The righting reflexes attempt to keep the eyes level with the horizon. In this case they will call for contraction of the lower lumbar paraspinal muscles on the right side to contract and straighten the body. These muscles invariably over react and now the torso is leaning posterior left. This creates a wedging force on the L-4 disc in particular. Usually this disc bulges toward the side of the anteriorly rotated ilium. This syndrome is the underlying, predisposing factor in most non-traumatic disc injuries. But I digress.

The righting reflexes decide that is a good start, and call the left lower thoracic paraspinals to contract. Probably some intercostal and other muscles as well. Now the body is leaning anterior-left again, just not as much as originally. Up the ladder of the body goes the pattern, contracting the upper thoracic paraspinals and whatever else can be recruited to help. This creates a high – low shoulder situation. Typically the left shoulder will be inferior as the most common pattern from the pronation syndrome is the “S” scoliosis. As this is a functional as opposed to an anatomical scoliosis, most orthopedics will call it an “Idiopathic” scoliosis, meaning they do not know why the patient has it. Fascinating, as we know why – from over-pronation. We would use foot-beds, soft-tissue manipulation, stretches, and exercise to correct the condition. They would do nothing unless the case is severe, whereupon they surgically insert rods along the spine.

Another component of the “Pronation Syndrome” is an apparent leg length discrepancy. When the ilium rotates anterior it usually projects the femur inferior, creating a long leg appearance when the patient is supine. I say usually. Sometimes, when the patient assumes the supine position the iliums correct and the legs equal out. Other times, the anterior rotation is accompanied by multiple other distortions patterns at the sacro-iliac joint, thus pulling the leg superior and it measures short. These are very unusual, but should you encounter such a case that does not follow the pattern, remember that anything is possible and nothing is always. This keeps things interesting.

## **Anatomical vs Functional Leg Length Discrepancy**

There are two types of leg length discrepancies. The first is anatomical. The second is functional. Anatomical discrepancy is when one tibia grows longer than the other, or one femur. In rare cases one ilium is smaller than the other, a “small hemi-pelvis.” Physical measurements from boney landmarks can assess for anatomical discrepancy, but the best way is special, multi-beam, calibrated X-rays. Fortunately, according to the research of Travell & Simons, only 10% of leg length discrepancies are anatomical.

Functional discrepancy is from distortion of the pelvis at the sacral-iliac joint, usually from anterior rotation of one ilium relative to the other. This author considers the anterior ilium to be the dysfunctional one. Some authors consider the posterior ilium, to be dysfunctional. Measurements of the angle formed by a line drawn through the ASIS – PSIS can determine which is truly at fault. Since 90% of leg length difference is functional, soft tissue therapists with proper training can have dramatic success in addressing such conditions.

What moves bones or holds them where they are? Muscles do both. Think about what muscles would have the potential to rotate an ilium anterior and which could rotate it posterior. In the anterior rotation distortion, which muscles would be short and need to be lengthened?

Continuing up the body, the cervical spine is tilting and the righting reflexes call on the muscles of the cervical region to make the last correction(s). This usually creates a lateral curve in the cervical spine with the final correction being made by the suboccipital muscles. Now the righting reflexes are happy, as the eyes are parallel with the horizon again. They tell the muscles to “hold it” and the pattern becomes a habit to the nervous system. Over time this distortion pattern causes significant damage and manifests as a variety of pain complaints. It is quite common for a person with “Pronation Syndrome” to seek help for headaches or neck pain. The overloaded suboccipitals can develop trigger points causing devastating “hat-band” and behind the eye headaches. The lateral deviating cervical curve sets the patient up for a cervical disk injury, bulge or rupture. This patient may not have any complaints below their neck at this time. However, they are a ticking time bomb in the lumbar spine, SI Joint, and knees. This author has seen many advanced Yoga practitioners with disk injuries or neurological complaints down their arms from inverted postures. Each one has had the “Pronation Syndrome” pattern.

This completes the quick tour of the pattern from toe to head. No matter what you do for the patient’s knee, pelvis, shoulder, or neck, the results will be temporary until something is done to support the foot and level the talus bone. Supporting the arch is not necessarily effective if the supporting appliance does not stabilize and align the calcaneus and talus. Exercises can strengthen the muscles that create the arches but even the most dedicated patient requires months of exercising to accomplish this. In the meantime, some form of supporting foot-bed or orthotic is advisable to allow progress to be made in unwinding the syndrome.

Begin screening your patients for the pronation syndrome and educating them about your findings. It will help them better understand their condition and they will more likely be receptive to a series of appointments as well as being compliant with homework assignments. They will also tend to refer people to you, giving you the opportunity to help more people. The vast majority of the cases in my private practice are based around the unwinding of the pronation syndrome. Once aware of this pattern you can begin to help more people faster and completely. This will bring happiness and satisfaction to both you and your patients. Best wishes for success!!

*Ralph Stephens LMT NCTMB [2008 Inductee - Massage Therapy Hall of Fame!] is an internationally recognized instructor, therapist and author, from Cedar Rapids, Iowa, who has been practising massage since 1986. One of a few master instructors in the profession, Ralph clearly presents what you need to know to help people in a way that you can take it home and use it immediately. He is known for making complex anatomical concepts easy to understand and fun to learn.*

*Ralph has worked with many world-class athletes and was Sports Massage Team leader for the 1990 World Disabled Skiing Championships. He’s produced 16 training videos, a textbook [Therapeutic Chair Massage] and many articles. He presents advanced continuing education seminars in Sports, Medical and Chair Massage, helping people like you help more people. In 1997 he was awarded the AMTA National Meritorious Award for commitment and dedication to the profession.*

*Don't miss an opportunity to study with this friendly, knowledgeable and inspiring instructor who believes learning should be a joyous experience! He'll be in the UK presenting at the SMTO Conference 2010 in Edinburgh on 27/28 March 2010. Look for another article from Ralph in the next issue of OTMS.*

## **SMTO CONFERENCE 2010 – 27/28 MARCH 2010 – EDINBURGH**

### **MEDICAL MASSAGE FOR THE ABDOMINAL WALL & SHOULDER GIRDLE “THE EL-TORSO CORSO” WITH RALPH STEPHENS, USA**

**Venue: Edinburgh Academy Junior School, 10 Arboretum Road EH3 5PL**

**Cost: £200 (SMTO members)/£250 (non-members)**

**Early Bird Discounts available – 10% off if paid in full by 31/12/09**

*Numbers strictly limited*

**Contact 01224 822960 or [info@scotmass.co.uk](mailto:info@scotmass.co.uk) for more details or to book**